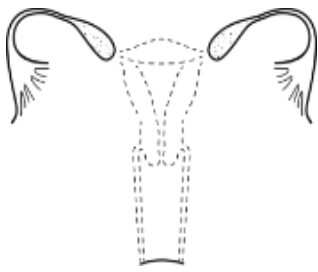




MÜLLERIAN AGENESIS

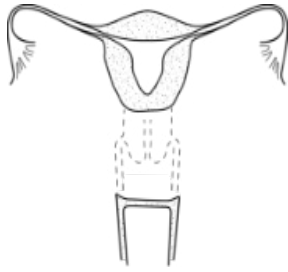


MÜLLERIAN AGENESIS

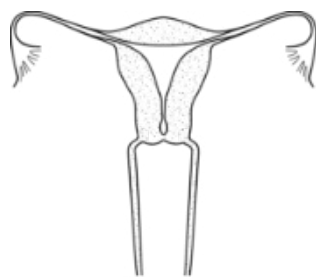


MÜLLERIAN AGENESIS WITH R/L ATROPHIC UTERINE REMNANT WITH FUNCTIONAL ENDOMETRIUM

CERVICAL AGENESIS

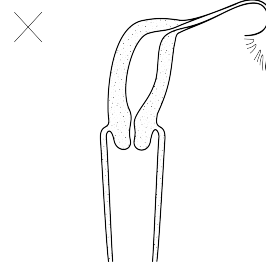


CERVICAL AGENESIS

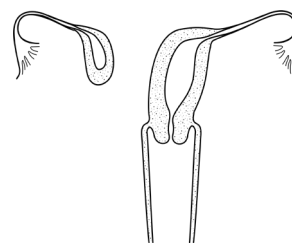


DISTAL CERVICAL AGENESIS

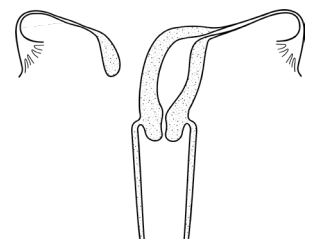
UNICORNUATE UTERUS



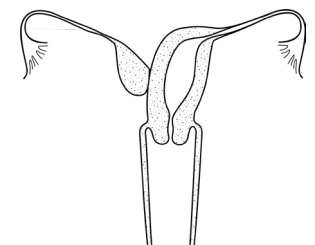
R/L UNICORNUATE UTERUS



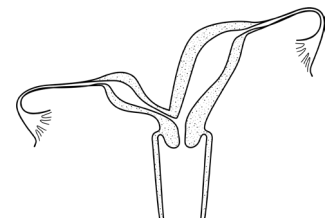
R/L UNICORNUATE WITH R/L DISTAL UTERINE REMNANT WITH FUNCTIONAL ENDOMETRIUM



R/L UNICORNUATE WITH R/L DISTAL ATROPHIC UTERINE REMNANT

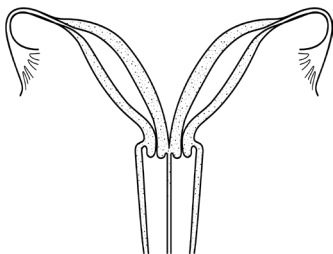


R/L UNICORNUATE WITH R/L ASSOCIATED ATROPHIC UTERINE REMNANT

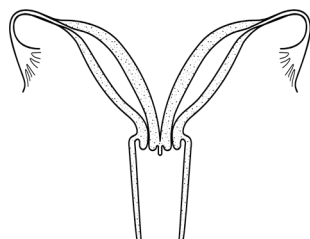


R/L UNICORNUATE WITH R/L UTERINE HORN COMMUNICATING AT LEVEL OF CERVIX

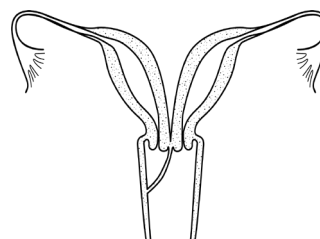
UTERUS DIDELPHYS



UTERUS DIDEPHYS AND LONGITUDINAL SEPTUM

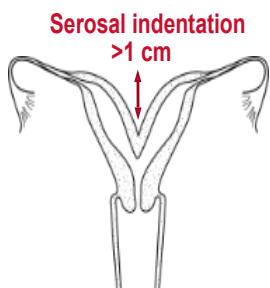


UTERUS DIDELPHYS AND +/- LONGITUDINAL VAGINAL SEPTUM OF VARIABLE LENGTH

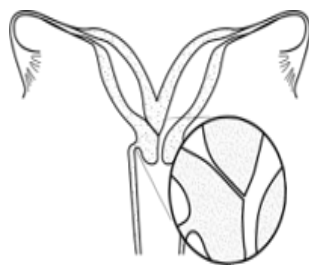

UTERUS DIDELPHYS AND OBSTRUCTED R/L HEMIVAGINA

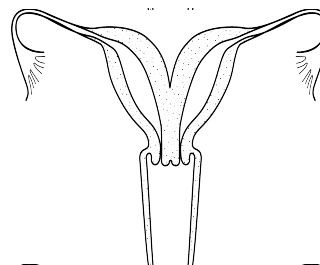
BICORNUATE UTERUS



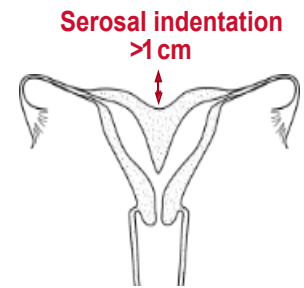
BICORNUATE UTERUS



BICORNUATE UTERUS WITH R/L COMMUNICATING TRACT



UTERUS BICORNUATE BICOLLIS

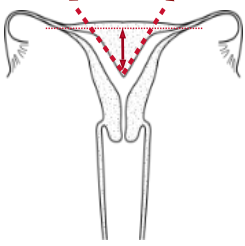


COMBINED BICORNUATE SEPTATE UTERUS

SEPTATE UTERUS

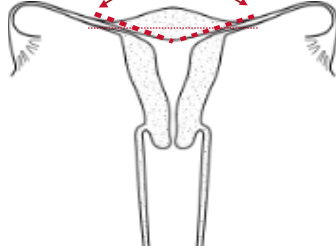
TRANSVERSE VAGINAL SEPTUM

Septum length >1 cm
Septum angle <90°

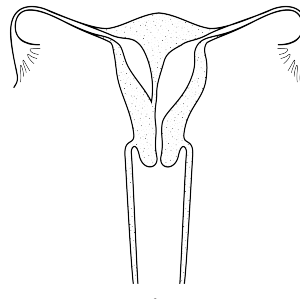


PARTIAL SEPTATE UTERUS

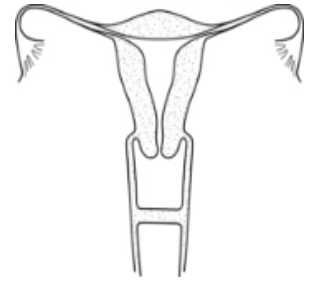
Arcuate distance ≤ 1cm
Angle >90° Normal: flat



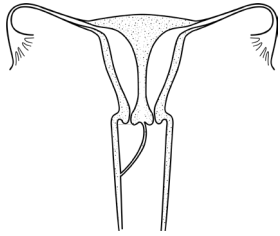
NORMAL/ARCULATE UTERUS



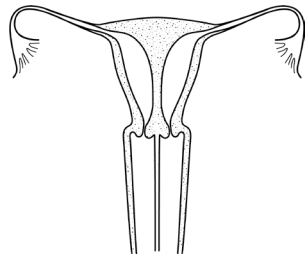
ROBERT'S UTERUS



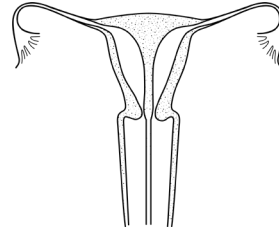
MID VAGINAL SEPTUM



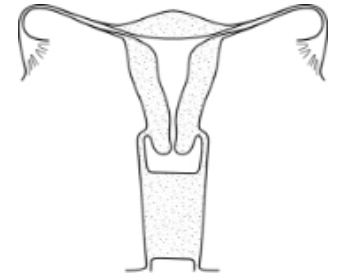
COMPLETE SEPTATE UTERUS,
DUPLICATED CERVICES, AND
OBSTRUCTED R/L HEMIVAGINA



COMPLETE SEPTATE UTERUS
WITH DUPLICATED CERVICES AND
LONGITUDINAL VAGINAL SEPTUM



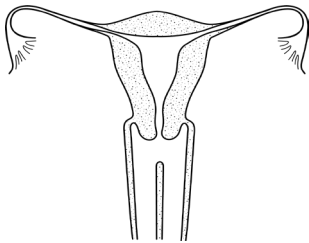
COMPLETE SEPTATE UTERUS WITH
SEPTATE CERVIX AND
LONGITUDINAL VAGINAL SEPTUM



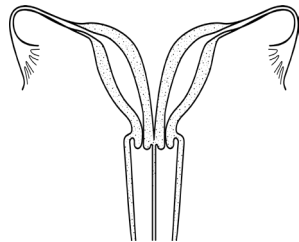
DISTAL VAGINAL AGENESIS

LONGITUDINAL VAGINAL SEPTUM

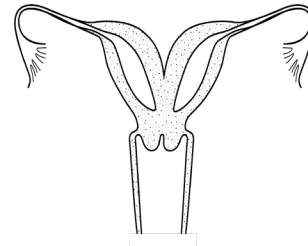
COMPLEX ANOMALIES



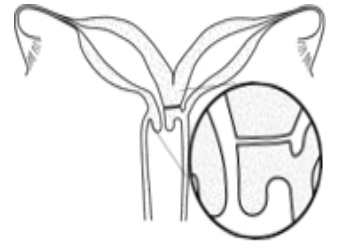LONGITUDINAL VAGINAL
SEPTUM OF VARIABLE LENGTH



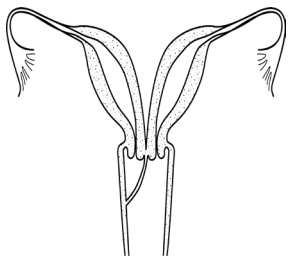
LONGITUDINAL VAGINAL
SEPTUM OF VARIABLE LENGTH
AND UTERUS DIDELPHYS



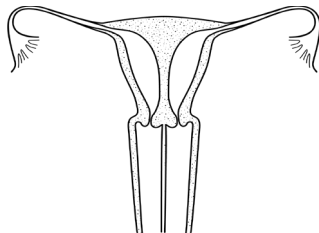
BICORNUATE UTERUS WITH
BILATERAL OBSTRUCTED
ENDOMETRIAL CAVITIES



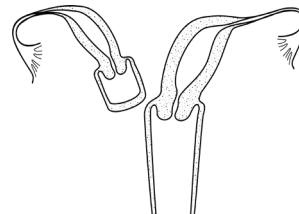
UTERUS DIDELPHYS WITH
COMMUNICATING HEMIUTERI AND
UNILATERAL R/L CERVICO-VAGINAL
ATRESIA



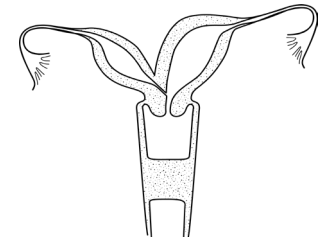
OBSTRUCTED R/L HEMIVAGINA
AND UTERUS DIDELPHYS



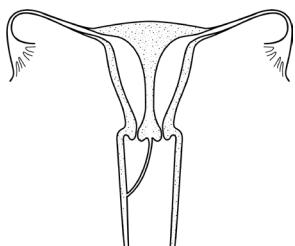
LONGITUDINAL VAGINAL
SEPTUM OF VARIABLE LENGTH
AND COMPLETE SEPTATE
UTERUS WITH DUPLICATED CERVIX



OBSTRUCTED R/L HEMIVAGINA,
HEMIUTERUS AND SINGLE CERVIX
WITH SEPARATE CONTRALATERAL
R/L PATENT HEMIUTERUS, CERVIX
AND VAGINA



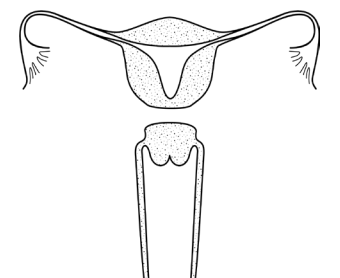
BICORNUATE UTERUS WITH
R/L COMMUNICATING TRACT AND
TRANSVERSE VAGINAL SEPTUM



OBSTRUCTED R/L HEMIVAGINA
AND COMPLETE SEPTATE UTERUS
WITH DUPLICATED CERVICES



Scan QR code to view the ASRM MAC 2021 tool (page 2 of 2)
©2021 American Society for Reproductive Medicine



UTERUS ISTHMUS AGENESIS